

FIBULAR TIBIALIZATION FOR THE RECONSTRUCTION OF SEGMENTAL TIBIAL DEFECTS

CLÁUDIO SILVA SANTOS¹, WALTER MORI JUNIOR¹, NATALINO LUCAS NETTO SANCHES¹, GABRIEL BARCELOS DE FREITAS¹,
GUSTAVO VIEIRA COSTA¹, JORGE MIGUEL GONZALES DUTRA¹

1. Unievangélica - Universidade Evangélica de Goiás Anápolis/GO, Brazil.

ABSTRACT

Introduction: Fibular tibialization, initially proposed by Hahn and later refined by Huntington, is a reconstructive technique used to manage extensive tibial segmental defects. It represents a biological autologous alternative, particularly valuable when conventional methods such as isolated bone transport or large grafting are not feasible. Gustilo-Anderson IIIC open tibial fractures remain among the most challenging orthopedic injuries, often requiring complex multidisciplinary limb salvage strategies. **Objective:** To report and analyze the first case of fibular tibialization performed at the Hospital Estadual de Anápolis Dr. Henrique Santillo (HEANA), emphasizing its applicability for limb salvage following high-energy trauma with extensive bone loss. **Case Report:** A patient involved in a motorcycle accident sustained a severe Gustilo-Anderson IIIC open fracture of the left tibia, associated with vascular injury and a 12 cm segmental bone defect. Initial management included temporary external fixation, fasciotomy, revascularization, and serial debridements. After adequate soft tissue coverage, fibular osteotomy and gradual medial transport were performed using an Ilizarov circular external fixator. The course required multiple surgical revisions, complementary tibial bone transport, autologous tricortical iliac crest grafting, and progressive consolidation. Late sequela included rigid equinus deformity, treated with ankle arthrodesis. **Conclusion:** Fibular tibialization combined with the Ilizarov technique is an effective limb salvage option for severe open tibial fractures with extensive segmental bone loss. This case highlights the importance of staged multidisciplinary management and demonstrates the feasibility of advanced reconstructive approaches in the Brazilian hospital setting.

Keywords: Tibia, Open fractures, Fibular tibialization, Ilizarov external fixator, Limb salvage, Segmental bone defect.

INTRODUCTION

Fibular tibialization, also known as the “fibula pro tibia” technique, was initially proposed by Hahn in 1884 as an alternative to fill extensive tibial defects through transposition of the ipsilateral fibula. Later, Huntington, in 1903, successfully applied this approach in a seven-year-old boy with a 12.7 cm tibial defect, using a pedicled vascularized graft in two stages, with establishment of proximal synostosis and observation of progressive graft hypertrophy after gradual weight-bearing.¹

The modern evolution of the technique especially emphasizes its use in children, with preservation

of the distal fibular growth plate. Baptista and collaborators highlight that autotransplantation of the distal fibular physis allows limb equalization during growth, being performed through a single approach and modification in the bone transposition route. This approach uses an arc-shaped incision that simultaneously reaches the tibial and fibular regions, allowing almost complete transposition of the fibula as an autologous biological solution, without the need for microsurgery.²

The procedure involves transfer of the fibula associated with the peroneal muscles and the tibialis anterior muscle, supported by a vascular pedicle from the peroneal vessels. This biological component of living bone favors a shorter consolidation time, greater remodeling capacity, superior resistance to infection, and better long-term mechanical properties.^{1,3}

The main indications for fibular tibialization include extensive tibial bone loss greater than 6 cm, failure of conventional reconstruction methods, adequate limb vascularization, preserved plantar sensation, and integrity of the ipsilateral fibula, even in cases of fracture that can still be used. In contrast, absolute contraindications include severe vascular compromise, uncontrolled active infection, loss of plantar sensation, and limited life expectancy.⁴

Several authors report that tibialization constitutes a viable option for limb salvage in cases of extensive tibial defects and complex healing. Tuli describes the technique as an effective alternative in difficult reconstructions, while Wood, in his 25-year experience with free vascularized fibular grafts, highlights satisfactory results when well indicated. However, complications such as nonunion, infection, angular deformities, limb shortening, and joint functional limitation are described in the literature as possible adverse outcomes.^{5,6}

Although bone transport using the Ilizarov technique is often considered the procedure of choice for extensive tibial defects, there are situations in which the tibial remnant is inadequate for lengthening, requiring alternative approaches. Catagni et al. described medial transport of the fibula with an Ilizarov fixator as an effective alternative in massive tibial bone loss. Intramedullary fixation has been considered biomechanically superior, allowing consolidation of the tibiofibular junctions and progressive hypertrophy within a few months, reaching dimensions comparable to the original tibia within up to three years.⁷

The present project aims to document and analyze a case of fibular tibialization performed at the Hospital Estadual de Anápolis Dr. Henrique Santillo (HEANA), this being the first procedure of this nature performed at the institution. Its relevance is related not only to the complexity of the technique, but also to the need to evaluate its applicability and effectiveness in the Brazilian hospital context. Thus, this study will contribute to the national literature in reconstructive orthopedics, offering clinical data and serving as a reference for professionals facing similar challenges.

Despite the generally favorable results described, in extremely severe cases it may be preferable to opt for immediate amputation, avoiding prolonged, painful treatments with risk of repeated failure that may eventually culminate in late amputation. Therefore, appropriate patient selection and a clear understanding of the indications and contraindications are fundamental to therapeutic success.

CASE REPORT

The patient was admitted on 08/06/2022 to HEANA, victim of a motor vehicle accident (motorcycle versus car collision), presenting with an extremely severe open fracture of the left tibia (Gustilo-Anderson IIIC), associated with extensive soft tissue loss and loss of distal perfusion.

Table 1 : Chronology of the Patient’s Care.

Date	Stage / Surgery	Procedure Performed	Objective / Observations
08/06/2022	Initial care (emergency)	Temporary external fixation + fasciotomy + revascularization (popliteal artery injury)	Damage control, limb salvage, and restoration of distal perfusion
08/06/2022	Follow-up surgery	Debridement + fasciotomy revision	Removal of devitalized tissues and initial contamination control
08/06/2022	Follow-up surgery	Debridement + resection of necrotic bone	Infection control and preparation of the bone bed
09/02/2022	Follow-up surgery	Debridement + Figueiredo-type dressing	Wound management and assistance in infection control
09/06/2022	Hospital discharge	—	After 30 days of hospitalization and multiple initial interventions
10/07/2022	Outpatient follow-up	Beginning of outpatient bone reconstruction follow-up	Initial identification of the bone defect
11/03/2022	Reconstructive evaluation	Tibial defect of approximately 12 cm	Therapeutic discussion: amputation vs. fibular tibialization
12/26/2022	Soft tissue reconstruction	Debridement + skin graft + flap on the left leg	Adequate coverage and preparation of the recipient bed
02/22/2023	Surgery 1	Fibular osteotomy + fixation with dynamic circular fixator (Ilizarov)	Beginning of the progressive transposition of the fibula to the tibia
03/01/2023	Surgery 2	Repositioning of the fixator + replacement of Schanz pins	Correction due to loosening of pins and continuation of transport
30/05/2023	Surgery 3	Complete transposition of the fibula + distal telescoping + distal osteotomy	Insertion into the distal tibial canal to promote consolidation

Date	Stage / Surgery	Procedure Performed	Objective / Observations
02/11/2023	Surgery 4	Revision due to hardware failure + replacement of metaphyseal pins + distal tibial osteotomy + new assembly	Proximal tibial bone transport to cover the residual defect
04/03/2024	Surgery 5	Enxerto ósseo tricortical autólogo da crista ílfaca	Proximal tibial bone transport to cover the residual defect
09/25/2024	Radiographic evaluation	Consolidação proximal e distal + consolidação do regenerado tibial	Evidence of satisfactory bone union
11/06/2024	Fixator removal	Removal of the circular fixator + joint manipulation	Gain in mobility and functional progression
12/11/2024	Rehabilitation	Progression to full weight-bearing + intensive physiotherapy	Motor recovery and biomechanical adaptation
25/02/2025	Surgery 6	Ankle arthrodesis + plantar flexor tenotomy	Correction of late sequela: rigid equinus foot
12/11/2025	Outpatient discharge	Complete consolidation + gait with residual claudication	Reduced muscle strength and functional limitation compatible with the initial severity

Surgery	Date	Procedure Performed
Surgery 1	22/02/2023	Transposition of the fibula to the tibia with dynamic circular fixator.
Surgery 2	01/03/2023	Repositioning of the fixator with replacement of Schanz pins.
Surgery 3	30/05/2023	Complete transposition of the fibula and distal osteotomy.
Surgery 4	02/11/2023	Revision due to hardware failure and proximal bone transport.
Surgery 5	03/04/2024	Tricortical bone graft from the iliac crest.
Surgery 6	25/02/2025	Ankle arthrodesis and correction of equinus foot.

Figure 1 : Data on surgeries and procedures performed.

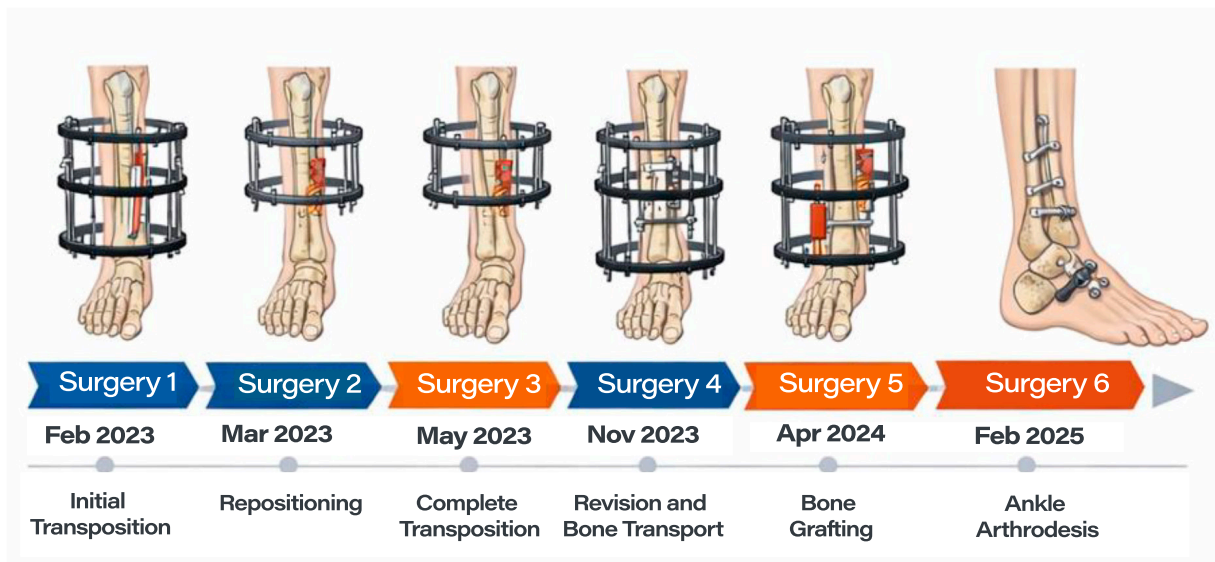


Figure 2: Models of the surgeries performed.

DISCUSSION

The presented case illustrates the complex reconstruction of a lower limb following high-energy trauma, culminating in a Gustilo-Anderson IIIC open fracture of the tibia with a 12 cm segmental bone defect. The decision to perform fibular tibialization, associated with bone transport using a circular Ilizarov fixator, represents a robust limb salvage strategy and is aligned with the scientific literature for cases of extreme severity.^{8,9}

The Gustilo-Anderson IIIC classification, characterized by arterial injury requiring repair for

limb viability, represents the extreme end of the spectrum of open fractures, with historically high amputation rates.¹⁰ A recent systematic study demonstrated that, although the decision between limb salvage and primary amputation remains controversial, functional outcomes and quality of life may be comparable between the two groups, reinforcing the validity of attempting reconstruction in selected patients.¹¹ The initial approach in this case, involving damage control, serial debridements, fasciotomy, and revascularization, followed the fundamental principles of severe trauma management, aiming at patient stabilization and the creation of a viable bed for subsequent reconstruction.¹²

The choice of fibular tibialization, or the Huntington procedure, was particularly appropriate given the extent of the bone defect. This technique, although described more than a century ago, remains a valuable alternative, especially when other options such as monofocal bone transport or free vascularized fibular grafting are unfeasible or present high risks.¹³ The main advantage of tibialization is the use of the ipsilateral fibula as a pedicled vascularized bone graft, which, once transposed to the tibial position and subjected to load, undergoes a process of adaptive hypertrophy, becoming capable of supporting body weight. Studies demonstrate that the tibialized fibula may reach diameters comparable to those of the contralateral tibia, a process that is more pronounced in younger patients, but which also occurs effectively in adults.¹⁴

The use of the circular Ilizarov fixator was crucial at multiple stages of treatment. Initially, it allowed the gradual transposition of the fibula, and later it was adapted to perform bone transport of the proximal tibial segment, addressing the residual defect. The Ilizarov technique, based on the principle of distraction osteogenesis, is considered the gold standard for the treatment of large bone defects, allowing regeneration of autologous bone and the simultaneous treatment of deformities and length discrepancies.¹⁵ The combination of tibialization with bone transport, as performed in this case, is a powerful hybrid approach that optimizes reconstruction by biologically filling large bone defects.

The long treatment time, extending for more than two years and involving multiple surgical interventions, is an inherent characteristic of these complex reconstruction processes. Complications such as pin loosening and hardware failure are relatively common and are part of the learning curve and the challenges associated with the prolonged use of external fixators.¹⁶ The proactive management of these complications, with planned surgical revisions, was fundamental to the final success of the treatment.

The sequela of rigid equinus foot, which required ankle arthrodesis, is a known complication and is frequently associated with severe lower limb trauma, neurological injuries, and long periods of immobilization with an external fixator. Arthrodesis, by creating a fused and stable joint, provides a plantigrade platform for gait, improving function and relieving pain, although at the expense of ankle mobility.¹⁷

CONCLUSION

The final outcome, with the patient ambulating under full weight-bearing despite residual functional limitations, should be considered a success. The literature supports that, for Gustilo IIIC fractures, the primary objective is the achievement of a functional and pain-free limb, and not necessarily the complete restoration of pre-injury function. The case demonstrates the effectiveness of a multidisciplinary and staged approach, combining plastic surgery techniques for soft tissue coverage and advanced

reconstructive orthopedic surgery for the treatment of the bone defect, resulting in limb preservation in a scenario with an extremely high risk of amputation.

REFERENCES

1. Rahimnia A, Fitoussi F, Penneçot G, Mazda K. Treatment of segmental loss of the tibia by tibialisation of the fibula: a review of the literature. *Trauma Mon.* 2012 Jan;16(4):154-9.
2. Baptista PPR, Guedes A, Reggiani R, Lavieri RF, Lopes JAS. Tibialização da fibula distal com preservação da placa epifisária: relato preliminar. *Rev Bras Ortop.* 1998;33(11).
3. Beris AE, Lykissas MG, Korompilias AV, Vekris MD, Mitsionis GI, Malizos KN, Soucacos PN. Vascularized fibula transfer for lower limb reconstruction. *Microsurgery.* 2011 Mar;31(3):205-11.
4. Freitas RJ, Cammarosano MA, Bozzola Filho Í, Bozola AR. Tibialização da fibula: relato de caso. *Rev. Brás. Cir. Plástico.* 2006;21:236-239
5. Tuli SM. Tibialization of the fibula: a viable option to salvage limbs with extensive scarring and gap nonunions of the tibia. *Clin Orthop Relat Res.* 2005 Feb;(431):80-4.
6. Wood MB. Free vascularized fibular grafting-25 years' experience: tips, techniques, and pearls. *Orthop Clin North Am.* 2007 Jan;38(1):1-12, v.
7. Catagni MA, Camagni M, Combi A, Ottaviani G. Medial fibula transport with the Ilizarov frame to treat massive tibial bone loss. *Clin Orthop Relat Res.* 2006 Jul;448:208-16.
8. Huntington TW. The classic: Case of bone transference. Use of a segment of fibula to supply a defect in the tibia. 1905. *Clin Orthop Relat Res.* 2012 Oct;470(10):2651-3.
9. Paley D, Maar DC. Ilizarov bone transport treatment for tibial defects. *J Orthop Trauma.* 2000;14(2):76-85.
10. Gustilo RB, Mendoza RM, Williams DN. Problems in the management of type III (severe) open fractures: a new classification of type III open fractures. *J Trauma.* 1984;24(8):742-6.
11. Ng HJH, Ang EJJ, Premchand AXR, O'daly BJ. Limb salvage versus primary amputation in Gustilo-Anderson IIIB and IIIC tibial fractures: a systematic review and meta-analysis. *Arch Orthop Trauma Surg.* 2023;143(7):4031-40.
12. Gopal S, Majumder S, Batchelor AGB, Knight SL. Fix and flap: the radical orthopaedic and plastic treatment of severe open fractures of the tibia. *J Bone Joint Surg Br.* 2000;82-B(7):959-66.
13. Widodo W, Wibowo A, Ifran I. Tibialization of fibula in critical bone defect due to post-debridement of chronic refractory osteomyelitis: case report. *Int J Surg Case Rep.* 2023;112:108935.
14. Puri A, Subin BS, Agarwal MG. Fibular centralisation for the reconstruction of defects of the tibial diaphysis and distal metaphysis after excision of bone tumours. *J Bone Joint Surg Br.* 2009;91-B(2):234-9.
15. Papakostidis C, Kanakaris NK, Pretel J, Faour O, Morell DJ, Giannoudis PV. Prevalence of complications of open tibial shaft fractures stratified as per the Gustilo-Anderson classification. *Injury.* 2011;42(12):1428-34.
16. Eralp L, Kocaoglu M, Rashid H. Reconstruction of segmental bone defects with circular external fixator and intramedullary nail. *Acta Orthop Traumatol Turc.* 2009;43(4):299-305.
17. Pinsker E, Daniels TR. AOFAS position statement: the role of arthrodesis in the management of advanced ankle arthritis. *Foot Ankle Int.* 2011;32(8):825-6.

MAILING ADDRESS

CLÁUDIO SILVA SANTOS

Avenida Brasil Norte, 3700 – Cidade Universitária, Anápolis /GO, Brasil.

E-mail: clauditos1@hotmail.com

EDITORIAL AND REVIEW

Chief editors:

Waldemar Naves do Amaral - <http://lattes.cnpq.br/4092560599116579> - <https://orcid.org/0000-0002-0824-1138>

Nílzio Antônio da Silva - <http://lattes.cnpq.br/1780564621664455> - <https://orcid.org/0000-0002-6133-0498>

Authors:

Cláudio Silva Santos - <http://lattes.cnpq.br/0398674557355009> - <https://orcid.org/0009-0004-3614-7829>

Walter Mori Junior - <http://lattes.cnpq.br/7818849273851069> - <https://orcid.org/0000-0002-2541-9567>

Natalino Lucas Netto Sanches - <http://lattes.cnpq.br/1086423666728939> - <https://orcid.org/0000-0003-0759-0827>

Gabriel Barcelos de Freitas - <http://lattes.cnpq.br/8709531391772547> - <https://orcid.org/0009-0002-5071-2201>

Gustavo Vieira Costa - <http://lattes.cnpq.br/0000-0002-3912-0363> - <https://orcid.org/0000-0002-3912-0363>

Jorge Miguel Gonzales Dutra - <http://lattes.cnpq.br/0838441334112116> - <https://orcid.org/0000-0002-9290-1644>

Library Review: Izabella Goulart

Spell Check: Dario Alvares

Translation: Soledad Montalbetti

Received: 17/03/26. Accepted: 20/03/26. Published in: 28/05/2026.