

DOUBLE DEMENTIA: THE ASSOCIATION BETWEEN NORMAL PRESSURE HYDROCEPHALUS AND SEMANTIC DEMENTIA

LEONARDO FERREIRA CAIXETA¹; GABRIELA DAMASCENO SILVA²; CIRO MENDES VARGAS³; YANLEY L NOGUEIRA⁴; IRON DANGONI FILHO⁵; VICTOR DE MELO CAIXETA⁶

1. Psychiatrist and Full Professor of Neuropsychiatry at the Faculty of Medicine of the Federal University of Goiás - FM-UFG, Director of CERNE – Center of Excellence in Neuropsychiatry at the Hospital das Clínicas of FM-UFG
2. Psychiatry resident at Hospital ASMIGO
3. Psychiatrist and Professor of Internal Medicine at the Faculty of Medicine of the Federal University of Goiás - FM-UFG
4. Psychiatrist, Master's student in the Health Sciences Graduate Program at the Faculty of Medicine of the Federal University of Goiás - FM-UFG
5. Neurologist, Master's degree holder in the Health Sciences Graduate Program at the Faculty of Medicine of the Federal University of Goiás - FM-UFG
6. Psychiatrist and Assistant Professor of Psychiatry at the Faculty of Medicine of the Federal University of Goiás - FM-UFG

ABSTRACT

Semantic Dementia (SD), which belongs to the group of Frontotemporal Lobar Degenerations, usually presents in the pre-senile stage, with no well-established risk factors. Normal Pressure Hydrocephalus (NPH) has been associated with neurodegenerative diseases; however, there are no descriptions in the literature regarding the association between SD and NPH. In this report, we present the case of a patient with congenital NPH and moderate intellectual disability who progressed to SD, highlighting the overlap of symptoms from both entities.

Keywords: Co-pathology, Temporal variant frontotemporal dementia, Semantic dementia, Frontotemporal lobar degeneration, Idiopathic normal pressure hydrocephalus.

INTRODUCTION

Semantic Dementia, also known as the temporal variant of Frontotemporal dementia, is a primary neurodegenerative disease within the group of Frontotemporal Lobar Degenerations, and is associated with asymmetric temporal atrophy.¹ It was initially described in patients with primary progressive aphasia, where they exhibit impairments in semantic memory, losing the meaning of words while preserving fluency.¹ Typically, symptom onset occurs in the pre-senile stage, around the age of 60, with no specific risk factors associated with the pathogenesis of Semantic Dementia.^{2,3}

Although hydrocephalus is a common imaging finding in dementias secondary to cortical atrophy, Normal

Pressure Hydrocephalus (NPH) as a nosological entity, with its own symptoms and causes, either congenital or acquired, is described as a cause of cognitive decline.

NPH presents with the triad of gait disturbance, cognitive impairment, and urinary incontinence. The most common comorbidities in patients with NPH are hypertension, Alzheimer’s disease (AD), and vascular dementia.^{4,5}

In NPH, beta-amyloid plaques and hyperphosphorylated tau protein inclusions are frequently identified in the frontal cortex, but the association of NPH with dementias from the Frontotemporal Lobar Degeneration (FTLD) group is not well described in the literature.⁶

As Semantic Dementia is rarely associated with NPH, we present this case in which the patient exhibits NPH, moderate mental retardation, alcohol abuse, multiple traumatic brain injuries (TBI), and the current outcome of Semantic Dementia.

CASE REPORT

IPJ, 68 years old, with a history of congenital hydrocephalus, moderate mental retardation, and inability to read and write.

At 13 years old, she started alcoholism with a preference for distilled spirits and an uncertain volume. She left her hometown at 38, leaving her children and husband, and spent 10 years as a homeless person in Rio de Janeiro. Throughout her life, she had several traumatic brain injuries (TBIs) secondary to alcohol consumption, requiring a decompressive craniectomy in 2010.

The family started noticing behavioral and cognitive changes in the patient at 54 years old, when she began wandering, increased alcohol consumption, and heteroaggressiveness. She was then admitted to a psychiatric hospital for 16 days. At 65, the children noticed spatial disorientation, prosopagnosia, Capgras syndrome, deficits in working memory, and episodic memory. Additionally, the patient became more irritable, with a low tolerance for frustration, suicidal ideation, and disgust behavior. At 66, family members described hyperorality, with reports that the patient ate all the food found around the house.

In the course of the illness, the patient showed improvement in irritability and suicidal ideation after starting sodium valproate. The return of disgust and improvement in episodes of mood elevation occurred after starting periciazine. She still has spatial and temporal disorientation, working memory deficits, and partially impaired episodic and autobiographical memory. Her speech is perseverative, focusing on returning to her hometown, and she continues to have prosopagnosia. She has adequate sleep, but still suffers from urinary and fecal incontinence, choking episodes, slowed gait, and motor rigidity. She does not have independence for performing instrumental activities or activities of daily living.

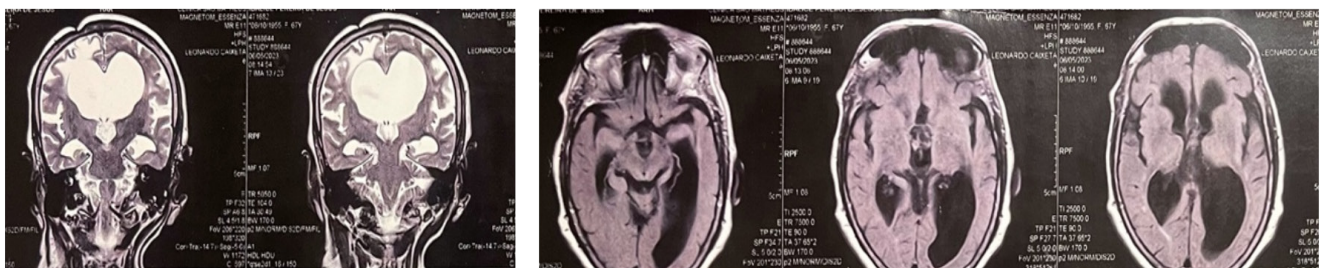


Figure 1 - Asymmetric hydrocephalus (more prominent in the left hemisphere), associated with degenerative atrophy in the temporal regions, also more pronounced in the left hemisphere.

DISCUSSION

Idiopathic normal pressure hydrocephalus has a complex multifactorial pathogenesis and is associated with Alzheimer's disease in many patients. To date, it is unknown whether a similar association exists with the temporal variant of frontotemporal lobar degeneration.⁶ Our case represents the first reported association between semantic dementia (SD) and normal pressure hydrocephalus (NPH), as far as we know. Although semantic dementia does not have established risk factors associated with its pathogenesis, it is known that in the presence of intellectual disability, there is reduced cognitive reserve, which may be associated with the earlier onset of symptoms in our case, observed by the family at least 6 years earlier than the average age described in the literature.

A recent study reported that the prevalence of idiopathic normal pressure hydrocephalus was much higher in the group of patients with the behavioral variant of frontotemporal lobar degeneration than in the group of patients with Alzheimer's disease (7.25% vs. 1.1%, respectively, $P = 0.02$). The authors also demonstrated that patients with a dual diagnosis share common clinical and paraclinical features of both idiopathic normal pressure hydrocephalus and the behavioral variant of patients with frontotemporal lobar degeneration, including the effectiveness of cerebrospinal fluid shunting in real-world experience. Overall, the results of these authors suggest a link between these two conditions and encourage neuropsychiatrists to consider idiopathic normal pressure hydrocephalus in patients with the behavioral variant of frontotemporal lobar degeneration in the presence of gait disturbances; the benefit/risk ratio could indeed favor shunt surgery for selected patients with this recently described entity.⁷

In patients with Semantic Dementia (SD), there are typically alterations in semantic memory, with the loss of words such as names of people or places. There is also difficulty in recognizing faces of people, even those who are close or have daily interactions. As the disease progresses, concepts are lost, and the difficulty in naming and recognition becomes increasingly intense.

In the patient IPJ, the onset of symptoms began with behavioral changes, such as wandering and aggressiveness, which may be associated with mood alterations and the fragility of frontal cognitive functions already affected by neurodevelopment, such as impulse control. Only after the age of 65 did the family manage to identify prosopagnosia and loss of disgust, which would be symptoms specifically related to semantic memory, but they also indicate significant cortical impairment. Today, just 3 years after the family's report, the patient already exhibits prosopagnosia for close relatives, severe anomia hindering communication, and topographic disorientation, which distinguishes this case from the typically more gradual progression of Semantic Dementia.

Throughout the patient's life history, only cognitive impairment secondary to NPH (Normal Pressure Hydrocephalus) was described. It was only in later years that the onset of gait disturbance and urinary incontinence appeared, coinciding with the worsening of the dementing syndrome, without corresponding new lesions in the white matter that would justify this deterioration.

In IPJ, there are confounding factors regarding the origin of the symptoms. Alcoholism and multiple TBIs (traumatic brain injuries) may have worsened the pre-existing neuronal damage and contributed to a reduction in cortical mass. Just as mood changes worsened symptoms such as aggression, irritability, reduced impulse control, and suicidal ideation, these symptoms were partly alleviated or resolved with the use of Valproic Acid.

In the T2 and T2 FLAIR MRI images, we observe significant ventriculomegaly and bitemporal atrophy, both

changes being more pronounced on the left side, with the temporal atrophy predominantly in the anterior region.

These exams accurately reflect the progression of the neurological lesions described in the report, where a disease causing neuroinvolvement affects a brain with cortical reduction due to a neurodevelopmental alteration.

A cohort study identified the underlying expansion of the C9ORF72 gene (associated with some forms of familial frontotemporal dementia, FTL) in patients with normal pressure hydrocephalus (NPH), providing evidence of a potential comorbidity between NPH and the FTL-ALS spectrum.⁷ These authors suggest that the analysis of C9ORF72 expansion should be considered for patients with probable NPH presenting with frontal atrophy and personality changes or other severe psychiatric symptoms.^{7,8}

REFERENCES

1. Caixeta L, Mansur LL. Demência semântica: avaliação clínica e de neuroimagem. *Arq Neuropsiquiatr* [Internet]. 2005 Jun [Cited 2024 Nov 8];63(2a):348-51. Available from: <https://www.scielo.br/j/anp/a/LTKFQT8fK7jzD74RYvGvng/> doi: 10.1590/S0004-282X2005000200030
2. Snowden JS, Goulding PJ, Neary D. Semantic dementia: a form of circumscribed atrophy. *Behav Neurol* [Internet]. 1989 [Cited 2024 Nov 8];2:167-82. Available from: <https://onlinelibrary.wiley.com/doi/10.1155/1989/124043> doi: 10.1155/1989/124043
3. Belliard S, Merck C, Jonin PY, Vérin M. Semantic dementia: aspects of the early diagnosis. *Revue Neurologique* [Internet]. 2013 Oct [Cited 2024 Nov 8];169(10):806-10. Available from: <https://www.sciencedirect.com/science/article/abs/pii/S0035378713008655> doi: 10.1016/j.neurol.2013.07.007
4. Malm J, Graff-Radford NR, Ishikawa M, Kristensen B, Leinonen V, Mori E,owler BK, Tullberg M, Williams MA, Relkin NR. Influence of comorbidities in idiopathic normal pressure hydrocephalus - research and clinical care. a report of the ISHCSF task force on comorbidities in INPH. *Fluids Barriers CNS* [Internet]. 2013 Jun 10 [Cited 2024 Nov 8];10(1):22. Available from: <https://fluidsbarrierscns.biomedcentral.com/articles/10.1186/2045-8118-10-22> doi: 10.1186/2045-8118-10-22
5. Williams MA, Relkin NR. Diagnosis and management of idiopathic normal-pressure hydrocephalus. *Neurol Clin Pract* [Internet]. 2013 Oct 3 [Cited 2024 Nov 8];3(5):375-85. Available from: <https://www.neurology.org/doi/10.1212/CPJ.0b013e3182a78f6b> doi: 10.1212/CPJ.0b013e3182a78f6b
6. Korhonen VE, Solje E, Suhonen NM, Rauramaa T, Vanninen R, Remes AM, Leinonen V. Frontotemporal dementia as a comorbidity to idiopathic normal pressure hydrocephalus (iNPH): a short review of literature and an unusual case. *Fluids Barriers CNS* [Internet]. 2017 Apr 19 [Cited 2024 Nov 4];14:10. Available from: <https://fluidsbarrierscns.biomedcentral.com/articles/10.1186/s12987-017-0060-7> doi: 10.1186/s12987-017-0060-7
7. Guilhem de Lataillade A, Boutoleau-Bretonnière C, Aguilar-Garcia J, Pallardy A, Bigot-Corbel E, Roualdes V, Leroy J, Damier P, Pouclet-Courtemanche H. Idiopathic normal pressure hydrocephalus and frontotemporal dementia: an unexpected association. *Brain Commun* [Internet]. 2022 Dec 14 [Cited 2024 Nov 8];4(6):fcac319. Available from: <https://academic.oup.com/braincomms/article/4/6/fcac319/6895872> doi: 10.1093/braincomms/fcac319
8. Korhonen VE, Remes AM, Helisalmi S, Rauramaa T, Sutela A, Vanninen R, Suhonen NM, Haapasalo A, Hiltunen M, Jääskeläinen JE, Soininen H, Koivisto AM, Leinonen V. Prevalence of C9ORF72 expansion in a large series of patients with idiopathic normal-pressure hydrocephalus. *Dement Geriatr Cogn Disord* [Internet]. 2019 [Cited 2024 Nov 8];47(1-2):91-103. Available from: <https://karger.com/dem/article-abstract/47/1-2/91/103387/Prevalence-of-C9ORF72-Expansion-in-a-Large-Series> doi: 10.1159/000497306

LEONARDO FERREIRA CAIXETA - <http://lattes.cnpq.br/9536747113677509> - <https://orcid.org/0000-0002-5736-9058>

GABRIELA DAMASCENO SILVA - <http://lattes.cnpq.br/3923250827555532> - <https://orcid.org/0000-0002-1698-9197>

CIRO MENDES VARGAS - <http://lattes.cnpq.br/2356866259871576> - <https://orcid.org/0000-0002-1904-5888>

YANLEY L NOGUEIRA - <http://lattes.cnpq.br/1045762578931468> - <https://orcid.org/0000-0003-1682-2714>

IRON DANGONI FILHO - <http://lattes.cnpq.br/5613534767423039> - <https://orcid.org/0000-0003-2822-4033>

VICTOR DE MELO CAIXETA - <http://lattes.cnpq.br/9968280872364556> - <https://orcid.org/0000-0003-2433-3128>

MAILING ADDRESS:

LEONARDO FERREIRA CAIXETA

5ª Avenida, s/n - Setor Leste Universitário - Goiânia - GO - Brazil

E-mail: leonardocaixeta@ufg.br

Library Review - Romulo Arantes

Spell Check: Dario Alvares

Received: 31/10/24. Accepted: 06/11/24. Published in: 14/11/24.

MAILING ADDRESS:

LUIZ EDUARDO MARTINS FREIRE

Rua Grão Pará 570 - Santa Efigênia - apt 803 - Ed. Terezinha Isaira - Belo Horizonte- MG - Brazil

E-mail: luiz-motta@hotmail.com

Library Review - Romulo Arantes

Spell Check: Dario Alvares

Received: 06/09/24. Accepted: 06/11/24. Published in: 12/11/24.