

HEADACHE WITH WARNING SIGNS ASSOCIATED WITH SUBDURAL HEMATOMA POST-SPINAL ANESTHESIA: A CASE REPORT OF A RARE COMPLICATION

LUIZ EDUARDO MARTINS FREIRE¹; MARIA RIBEIRO TOLEDO PIZA¹; LUIZ HENRIQUE RIBEIRO MOTTA²

1. Pontifícia Universidade Católica of Goiás - Goiânia - GO - Brazil
2. Universidade de Rio Verde, Campus Aparecida de Goiânia - GO - Brazil

ABSTRACT

Introdução: Post-spinal anesthesia headache is a common complication, but the occurrence of a subdural hematoma is rare and may present with warning signs that require immediate attention. **Objetivos:** The objective of this report is to present a case of headache with warning signs associated with a subdural hematoma, diagnosed after spinal anesthesia performed with a fine-gauge needle and a single puncture, emphasizing the importance of early recognition and appropriate management of this rare complication. **Case Report:** A 50-year-old female patient with uterine cancer, undergoing radiotherapy, developed actinic cystitis and urethrorrhagia without hemodynamic or hematimetric alterations. She underwent spinal anesthesia for intra-vesical cauterization using a 27G Quincke needle with a single puncture. The surgical procedure was uneventful. After 48 hours, she developed a sudden onset of severe bilateral occipital headache (8/10), associated with nausea and vomiting. This was interpreted as a post-dural puncture headache (hypotension) and was treated with fluids, caffeine, and analgesics by the medical team. She returned to the emergency department 13 days later with a worsening headache, decreased level of consciousness, and dense brachiorural hemiparesis on the left side. A cranial CT scan revealed a chronic right frontoparietal subdural hematoma with mass effect and midline shift. She was taken to the operating room for hematoma drainage. After trepanation, hypertensive hematoma drainage was observed. The procedure was uneventful, and the patient remained hospitalized for 5 days for monitoring and was discharged with complete recovery from deficits. **Discussion:** This case highlights the importance of differentiating benign headaches from serious secondary conditions. We reviewed the literature on the incidence, pathophysiology, and management of post-spinal anesthesia subdural hematomas. However, intracranial subdural hematoma constitutes a rare complication, with an incidence ranging from 1:500.000 to 1:1.000.000. The pathophysiological mechanism remains uncertain, though the leading hypothesis suggests that the loss of cerebrospinal fluid through the needle puncture causes a volumetric and pressure decrease in the dynamics of the closed circulatory system, leading to gravity-dependent brain displacement. This results in traction of cerebral structures and rupture of bridging veins. Consequently, the case illustrates a rare complication with nonspecific

symptoms, making the early diagnosis of subdural hematoma challenging, which, if neglected, can result in a fatal outcome. This case emphasizes the importance of distinguishing benign headaches from serious secondary conditions. We review the literature on the incidence, pathophysiology, and management of subdural hematomas following spinal anesthesia. Conclusion: Early recognition of warning signs in patients with headaches following spinal anesthesia is crucial to prevent adverse outcomes. Subdural hematoma should be considered in the differential diagnosis of headaches with warning signs.

Keywords: post-dural puncture headache, subdural hematoma, neuroimaging, signs and symptoms.

INTRODUCTION

Certain complications of lumbar punctures are well-known and documented, such as low back pain, radicular injuries, abscesses, and meningitis. However, chronic subdural hematoma following spinal anesthesia is a rare condition, with only 33 cases reported in the literature.¹ The exact prevalence is unknown, but the rarity of cases suggests an exceptionally low occurrence, with an estimated incidence of 1 in 500,000 to 1,000,000 people.² The initial presentation can be nonspecific, such as headache, which often leads to diagnoses and treatments that do not address the underlying severity.

This case underscores the importance of recognizing warning signs in patients presenting with post-spinal anesthesia headache, highlighting the need for careful neurological evaluation and, when indicated, the use of neuroimaging to identify potential serious complications. Early intervention, such as the performed surgical drainage, can be crucial for the complete recovery of neurological deficits.

Therefore, the objective of this paper is to report the case of a subdural hematoma following spinal anesthesia performed with a fine-gauge needle and single puncture, emphasizing that characterizing the headache is essential for the early diagnosis of this potentially fatal complication.

MATERIALS AND METHODS

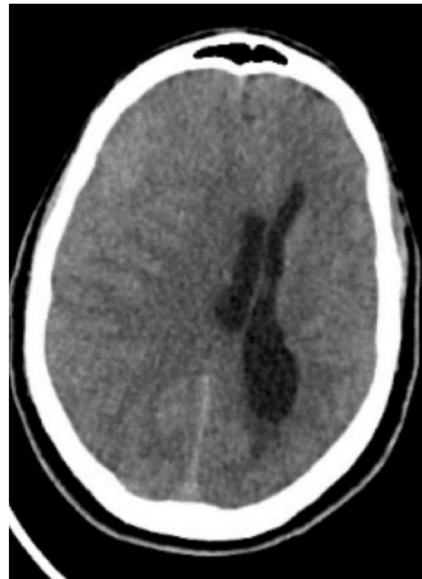
This is a case report study. A detailed analysis of the patient's medical record and clinical observations was conducted. Informed consent was obtained from the patient for the use of data in the case report, ensuring confidentiality and anonymity. The study was conducted in accordance with ethical guidelines and applicable regulations for medical case reports.

CASE REPORT

A 50-year-old female patient with uterine cancer undergoing radiotherapy developed radiation cystitis and urethrorrhagia, with no hemodynamic or hematimetric changes. She underwent spinal anesthesia for intravesical cauterization using a 27G Quincke needle and single puncture. The surgical procedure was uneventful. After 48 hours, she presented with a sudden onset of severe bilateral occipital headache (8/10 intensity), accompanied by nausea and vomiting. This was interpreted as post-puncture headache due to cerebrospinal fluid hypotension and was treated with fluids, caffeine, and analgesics by the internal medicine team.

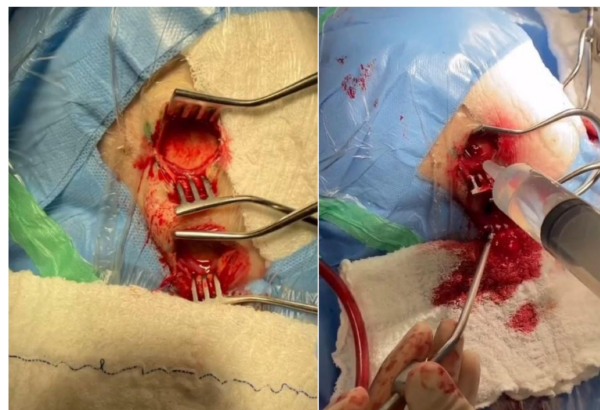
She returned to the emergency department 13 days later with worsening headache, decreased level of consciousness, and dense brachioradial hemiparesis on the left side. A cranial CT scan (Figure 01) revealed a right frontoparietal chronic subdural hematoma with mass effect and midline shift.

Figure 01: Non-contrast cranial CT (Axial view) – showing an acute-on-chronic right subdural hematoma.
Source: Personal archive 03/2023.



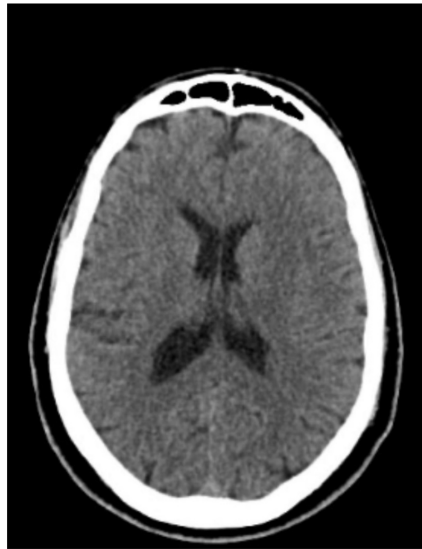Assessed by the on-call neurosurgery team in the emergency department, the surgical approach was discussed with the patient and her family. She was taken to the operating room for hematoma drainage. Two burr holes were made (right frontal and right parietal). After trepanation and durotomy, a pressurized, chronic hematoma drained out (Figure 02). The cavity was thoroughly irrigated with 0.9% saline solution. The procedure was uneventful, with adequate brain re-expansion observed at the end.

Figure 02: Right frontal and parietal burr holes. Thorough cavity irrigation. Source: Personal archive – 03/2023



The patient remained hospitalized for 5 days for monitoring and was discharged with complete improvement of the deficits. In an outpatient follow-up visit 15 days after hospital discharge, she remained without deficits and showed significant improvement in the headache. A postoperative control CT scan (Figure 03) was performed 3 months after surgery, showing no residual signs of intracranial bleeding.

Figure 03: Control cranial CT scan – 3 months post-surgery (Axial view – without contrast).
Source: Personal archive – 06/2023.



DISCUSSION

The case of a 50-year-old patient with a history of uterine cancer undergoing radiotherapy, who developed radiation cystitis and urethrorrhagia, clearly and concerningly illustrates the potential complications of spinal anesthesia. The development of post-dural puncture subdural hematoma (PDPSDH) is a rare and severe complication of spinal anesthesia, with an estimated incidence of 1 in 500,000 to 1.000.000 people², especially in obstetric patients, who often present with post-dural puncture headache (PDPH) as a common manifestation.³ While PDPH is mostly self-limiting and benign, progression to a subdural hematoma represents a significant risk for morbidity and mortality, requiring prompt attention and early intervention.⁴

The primary etiology of PDPSDH is intracranial hypotension resulting from continuous cerebrospinal fluid (CSF) leakage through the dural defect, which can lead to rupture of the bridging veins and subsequent formation of a subdural hematoma⁵. The transformation of postural headache, typical of PDPH, into a non-postural headache, accompanied by neurological symptoms such as vomiting, seizures, cognitive changes, or focal neurological signs, should be considered an important warning sign for the development of a subdural hematoma.⁶

Computed tomography (CT) is often the first imaging modality used to diagnose subdural hematoma due to its availability and rapid detection capability.⁷ However, magnetic resonance imaging (MRI) may be more effective in subacute and chronic stages, where differentiation between hematoma and brain tissue can be challenging on CT.⁸ The management decision for PDPSDH should be based on the extent of the hematoma, presence of

neurological impairment, and associated symptoms.⁹ Small subdural hematomas can be managed conservatively with strict monitoring, while larger hematomas or those associated with progressive neurological deficits require surgical intervention.¹⁰

The differentiation between PDPH and PDPSDH is crucial, as inadequate or delayed treatment can result in significant adverse outcomes.¹¹ Early and thorough evaluation, using the guidelines from the International Headache Society to identify warning signs, is essential to prevent severe complications. Alarm signs include sudden or severe onset of headache, change in pain characteristics, advanced age, history of cancer, papilledema, signs of central nervous system infection, focal neurological signs, and a history of immunosuppression.¹² The presence of these signs should prompt further investigation to ensure early identification and appropriate management of complications.^{13,14}

CONCLUSION

Headache with warning signs after spinal anesthesia should be thoroughly investigated, especially in obstetric patients, due to the risk of complications such as subdural hematoma. The transformation of a postural headache into a non-postural one, associated with other neurological symptoms, is a critical indicator for suspecting PDPSDH. The reported clinical experience demonstrates that early recognition and timely surgical management can result in complete recovery, even in cases of severe complications such as subdural hematoma.

Furthermore, this case also illustrates the complexity of differentiating between PDPH and PDPSDH, especially in patients with additional risk factors, such as prior radiotherapy treatment. Management of PDPSDH should be individualized, with options ranging from careful observation in cases of small hematomas to surgical intervention in more severe cases.

Ultimately, awareness of this complication and readiness for diagnostic investigation are essential for the safety and well-being of patients undergoing spinal anesthesia.

REFERENCES

1. Amorim JA, Anjos Remígio DSC, Damázio Filho O, Barros MAG, Carvalho VN, Valença MM. Intracranial subdural hematoma post-spinal anesthesia: report of two cases and review of 33 cases in the literature. *Rev Bras Anesthesiol.* 2010 Nov-Dec;60(6):620-9.
2. Bisinotto FMB, Dezena RA, Fabri DC, Abud TMV, Canno LH. Hematoma subdural intracraniano: uma rara complicação após raqui-anestesia: relato de caso. *Rev Bras Anesthesiol.* 2012; 62(1): 92-5.
3. Wu CL, Rowlingson AJ, Cohen SR, Michaels RK, Courpas GE, Joe EM, Liu SS. Gender and post-dural puncture headache. *Anesthesiology.* 2006 Sep;105(3):613-8.
4. Ansari JR, Barad M, Shafer S, Flood P. Chronic disabling postpartum headache after unintentional dural puncture during epidural anaesthesia: a prospective cohort study. *Br J Anaesth.* 2021 Oct;127(4):600-7.
5. Berrocal VM, Cornejo R, Berrocal AV. Neuraxial anaesthesia-related intracranial subdural haematoma: a diagnostic dilemma. *BMJ Case Rep.* 2011;2011:bcr0520103056.
6. Schievink WI. Spontaneous spinal cerebrospinal fluid leaks and intracranial hypotension. *JAMA.* 2006 May 17;295(19):2286-96.
7. Patel R, Urits I, Orhurhu V, Orhurhu MS, Peck J, Ohuabunwa E, Sikorski A, Mehrabani A, Manchikanti L, Kaye AD, Kaye RJ, Helmstetter JA, Viswanath O. A Comprehensive Update on the Treatment and Management of Postdural Puncture Headache. *Curr Pain Headache Rep.* 2020 Apr 22;24(5):20.

8. Shaikh N. Emergency management of headache. *Prim Care*. 2004;31(1):243-61.
9. Kamel H, Navi BB, Nakagawa K, Hemphill JC, Ko NU. Spinal anesthesia and subdural hematoma in women with arteriovenous malformations: a population-based study. *Anesthesiology*. 2014;121(4):883-9.
10. Imbelloni LE, Sobral MGC, Carneiro ANG. Cefaleia pós-raquianestesia e o desenho das agulhas. experiência de 5050 casos. *Rev Bras Anesthesiol*. 2001;51(1):43-52.
11. Gaiser R. Postdural puncture headache. *Curr Opin Anaesthesiol*. 2006 Jun;19(3):249-53.
12. Headache Classification Committee of the International Headache Society (IHS). The International Classification of Headache Disorders, 3rd edition (beta version). *Cephalalgia*. 2013 Jul;33(9):629-808.
13. Scott DB, Hibbard BM. Serious non-fatal complications associated with extradural block in obstetric practice. *Br J Anaesth*. 1990 May;64(5):537-41.
14. Alilou M, Halefadi S, Caidi A, S Kabbaj, H Ismaili, W Maazouzi. Une nouvelle observation d'hématome sous-dural chronique intracrânien au décours d'une rachianesthésie. *Ann Fr Anaesth Reanim*, 2003 Jun;22(6): 560-1.

LUIZ EDUARDO MARTINS FREIRE - <http://lattes.cnpq.br/2273033115809464> - <https://orcid.org/0009-0008-0381-6896>

MARIA RIBEIRO TOLEDO PIZA - <http://lattes.cnpq.br/9822470149541417> - <https://orcid.org/0009-0000-9417-6020>

LUIZ HENRIQUE RIBEIRO MOTTA - <http://lattes.cnpq.br/8442935850378284> - <https://orcid.org/0009-0002-0046-5492>

MAILING ADDRESS:

LUIZ EDUARDO MARTINS FREIRE
Rua Grão Pará 570 - Santa Efigênia - apt 803 - Ed. Terezinha Isaira - Belo Horizonte- MG - Brazil
E-mail: luiz-motta@hotmail.com

Library Review - Romulo Arantes

Spell Check: Dario Alvares

Received: 06/09/24. Accepted: 06/11/24. Published in: 12/11/24.